

Common Limb Fractures



Mr Sheraz Malik MB BS MRCS
Instructor

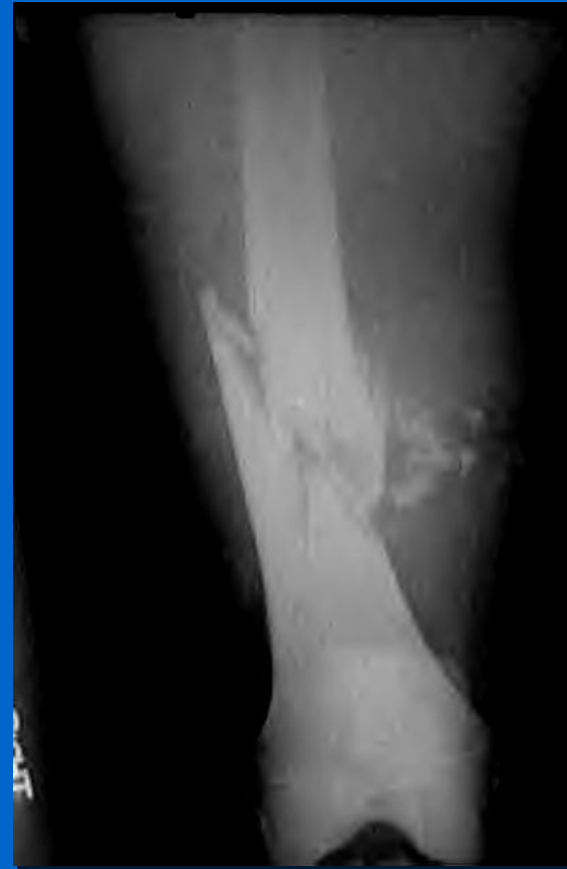
Mr Paul Ofori-Atta Mb ChB FRCS
President Motc Life UK April 2009

Objectives

- To be able to describe all characteristics of a fracture
- Describe the three principles of management of closed fractures
- Describe and classify the most common fractures

Fracture Description

- Site
- Level
- Deformity (pattern)
- Displacement
- Angulation
- Intra/extra-articular
- Open/Closed



Management

- ATLS guidelines
- Full assessment of patient
 - ‘treat the patient & not the part’

The 3 principles of any fracture Management

1. Reduce
2. Hold
3. Rehabilitate

Reduce

- Closed reduction
- Open reduction

Hold Reduction

- Cast splintage
- Continuous traction
- Functional bracing
- Internal fixation
- External fixation

Rehabilitation

- Reduce oedema
- Preserve joint movement
- Restore muscle power
- Resume normal activity

Summary

- You can describe the character of a fracture
- You know the 3 principles of the management of closed fractures

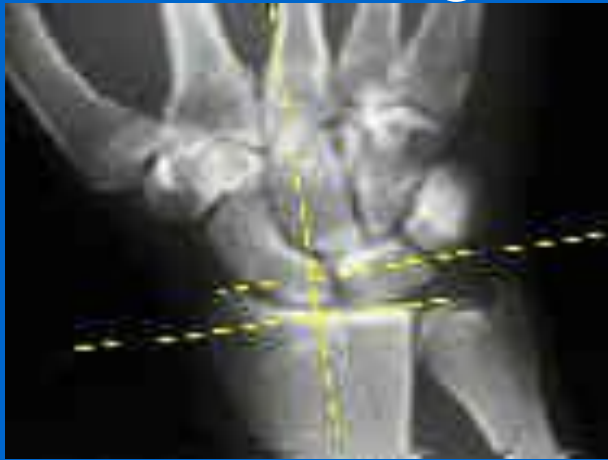Distal Radius Fractures

What are we going to talk about?

- Colles #
- Smith's #
- Barton's # - dorsal + volar
- Chauffeur's #
- Intra-articular #

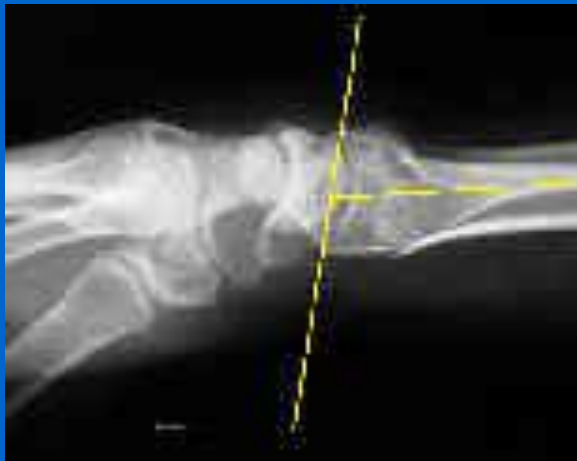Important radiographic features

Radial Height

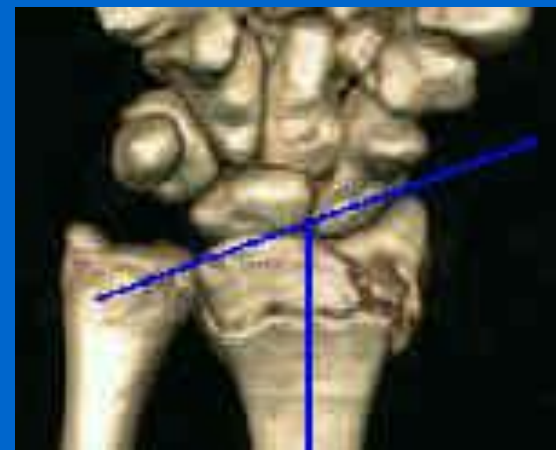

Intra-articular component

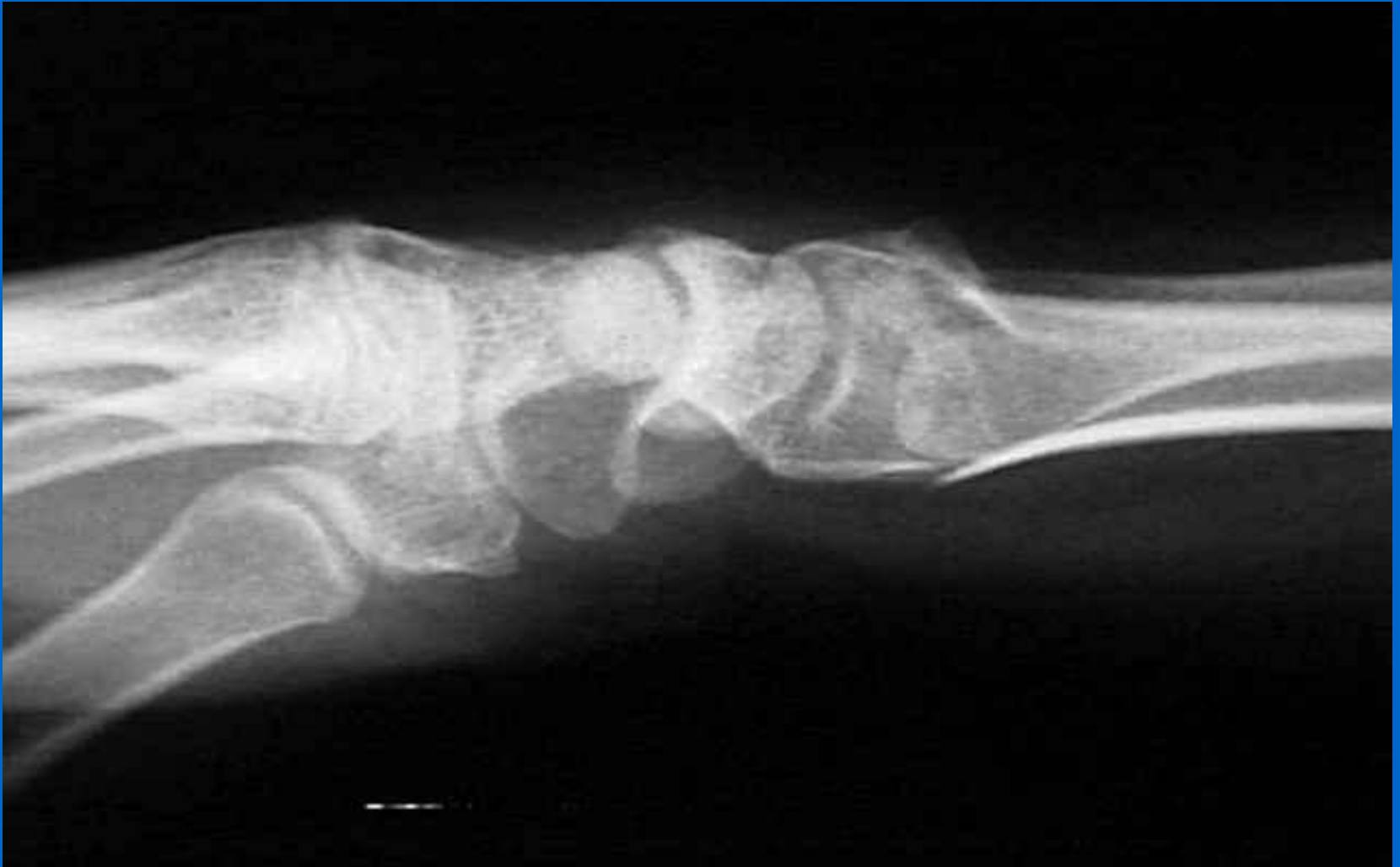Volar tilt



Radial Inclination



Colles



Colles # Treatment & Complications

- Reduction in A&E and dorsal backslab
- MUA & K-wiring
- Bridging ex-fix
- EPL rupture
- RSD
- Median nerve compression
- Malunion

Smith's

- Extra-articular palmarly displaced + increased volar tilt

CLASSIFICATION

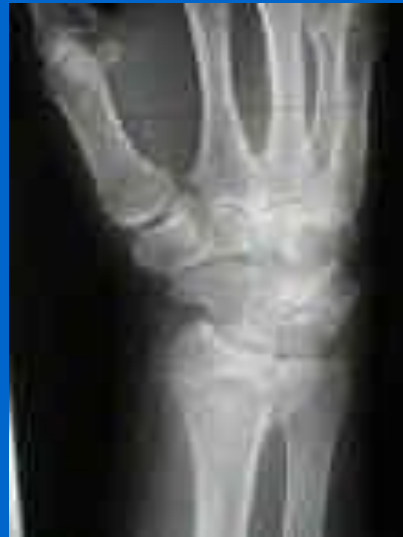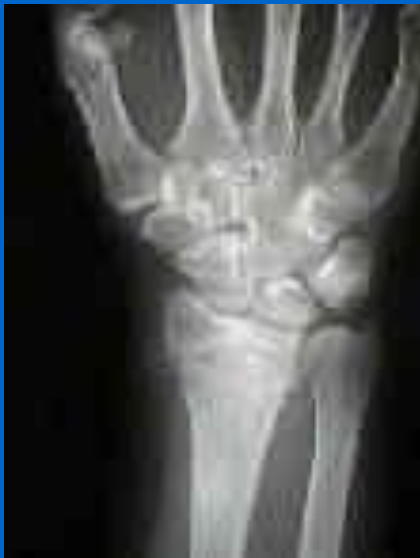1. Extra-articular
2. Crosses into the dorsal articular surface
3. Enters radiocarpal joint (Volar Barton's)

Smith's treatment

- Reduction – with long arm cast
 - Forearm in supination & wrist in dorsiflexion
- ORIF

Dorsal Barton's

- Intra-articular distal radius fracture +/- dislocation radiocarpal joint
- Most common #/dislocation of wrist joint
- Often occurs along with radial styloid

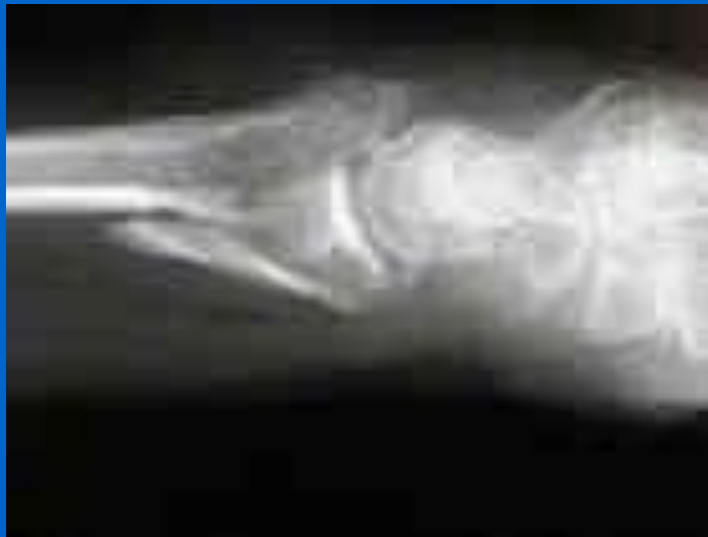

Dorsal Barton's Treatment

- Non-op often fails
- Manipulation technique same as Colles
- Stability of reduction best obtained with wrist extension to take advantage of intact volar carpal ligament
- MUA + K-wire vs Dorsal ORIF

Volar Barton's

- More common than dorsal Barton's
- Similar to Smith's type II
- Volar margin fracture carpal surface associated with subluxation radiocarp jt.

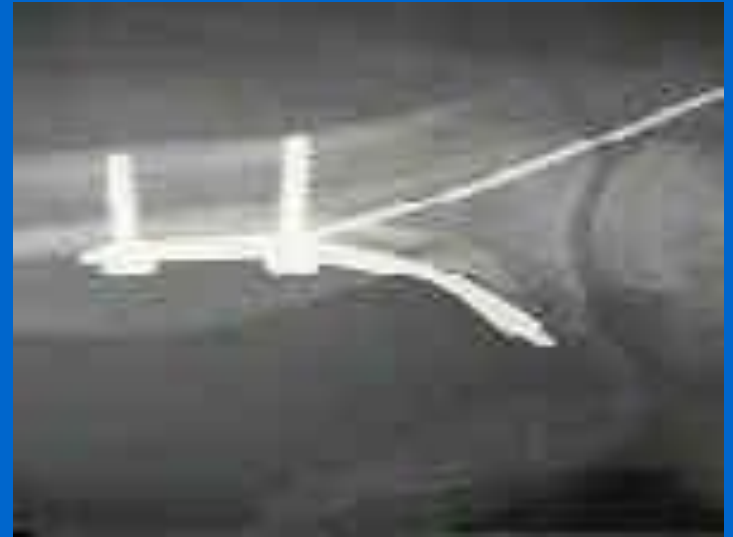
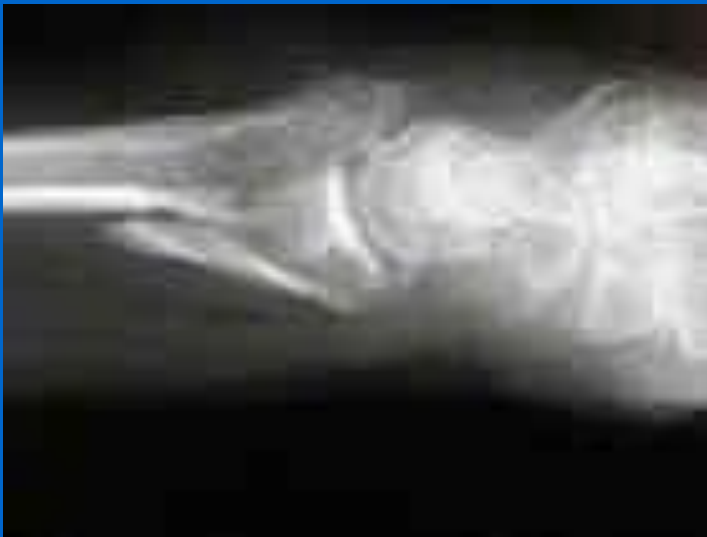

Chauffeur's Fracture Treatment

- Operative
 - K-wire (small incision over 1st compartment)
 - Cannulated lag screw
- Indications for formal ORIF
 1. Rotational displacement
 2. Interposed tissue (FCR, rarely extensors)
 3. Metaphyseal defect after reduction requiring bone graft

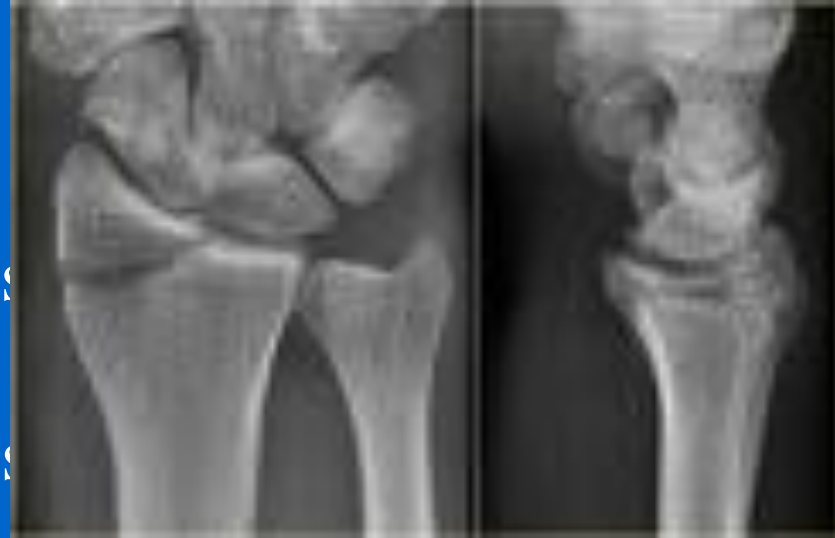Volar Barton's Treatment

- Most will require op treatment
- If nonop – ensure wrist immobilised in palmar flexion
- ORIF



Chauffeur's Fracture

- Radial styloid
- Strong radiocarpal ligament (radioscaphocapitate) avulses distal radius metaphysis
- Brachoradialis & long extensors generate displacing forces
- Rad styloid # often accompanied by dislocations of lunate
- Evaluation should include supinated view so that scapholunate ruled out



Intra-articular fractures

Frykman classification

I - extra-articular

II- with ulna styloid

III - intra-articular radiocarpal

IV - with ulna styloid

V – intra-articular involving RUJ

VI – with ulna styloid

VII - both joints

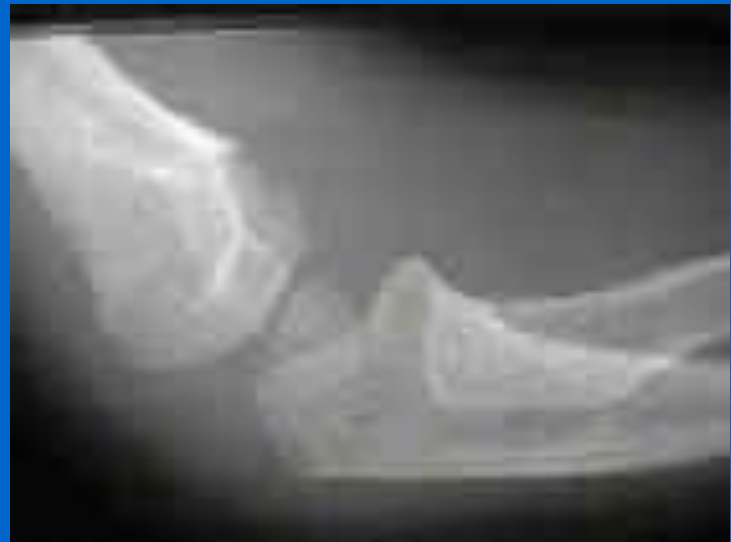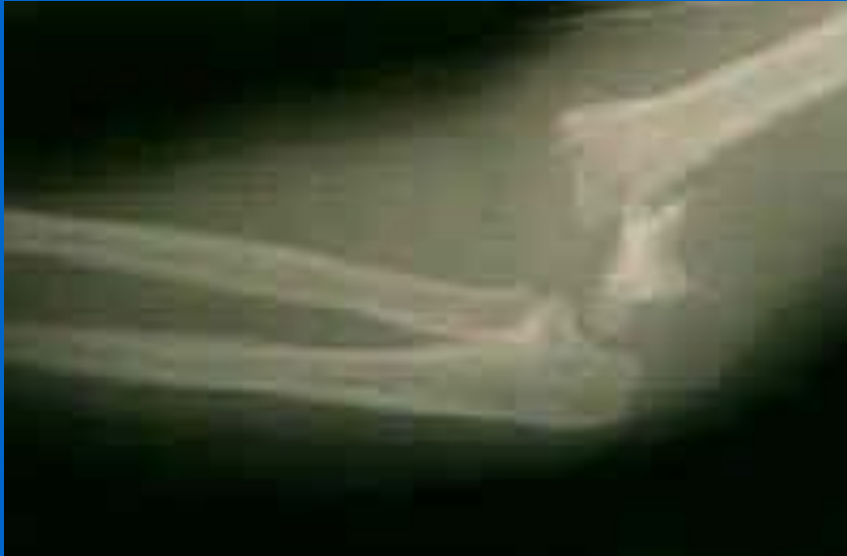VIII - with ulna styloid

Paediatric Supracondylar Fractures

Could present as an emergency.

Classification

- 2 types: Extension (95%) & Flexion (5%)
- Extension type classified according to Gartland:
 1. Non-displaced
 2. Displaced, posterior cortex intact
 3. Displaced with no cortical contact
- Palpate distal radius for frx (occurs in 5-6%)



Flexion Type

- 5% - similar classification
- Elbow flexed as it hits ground
- Post cortex fails first
- Distal fragment displaced anteriorly and laterally
- Soft tissue swelling less & neurovasc comp rare
- Ulnar nerve palsy by prox bone spike

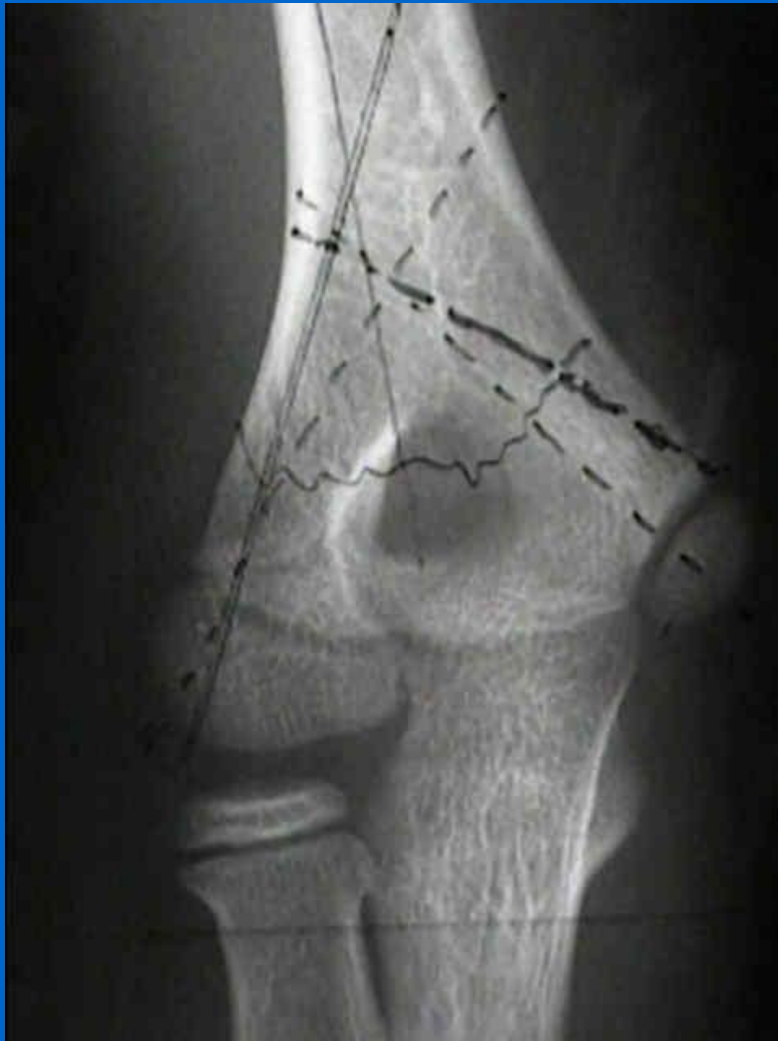Extension Type

- 95% cases
- FOOSH w hyperextension elbow
- Nerves & blood vessels are contused, compressed or lacerated

Radiographic Evaluation

- AP view
 - No more than 4 deg varus (as determined by Bauman's angle)
 - Should we get XR of contralateral elbow?
- Lat view (get true lat)
 - Ant & sup displ of fat pad in type I

Baumann's Angle

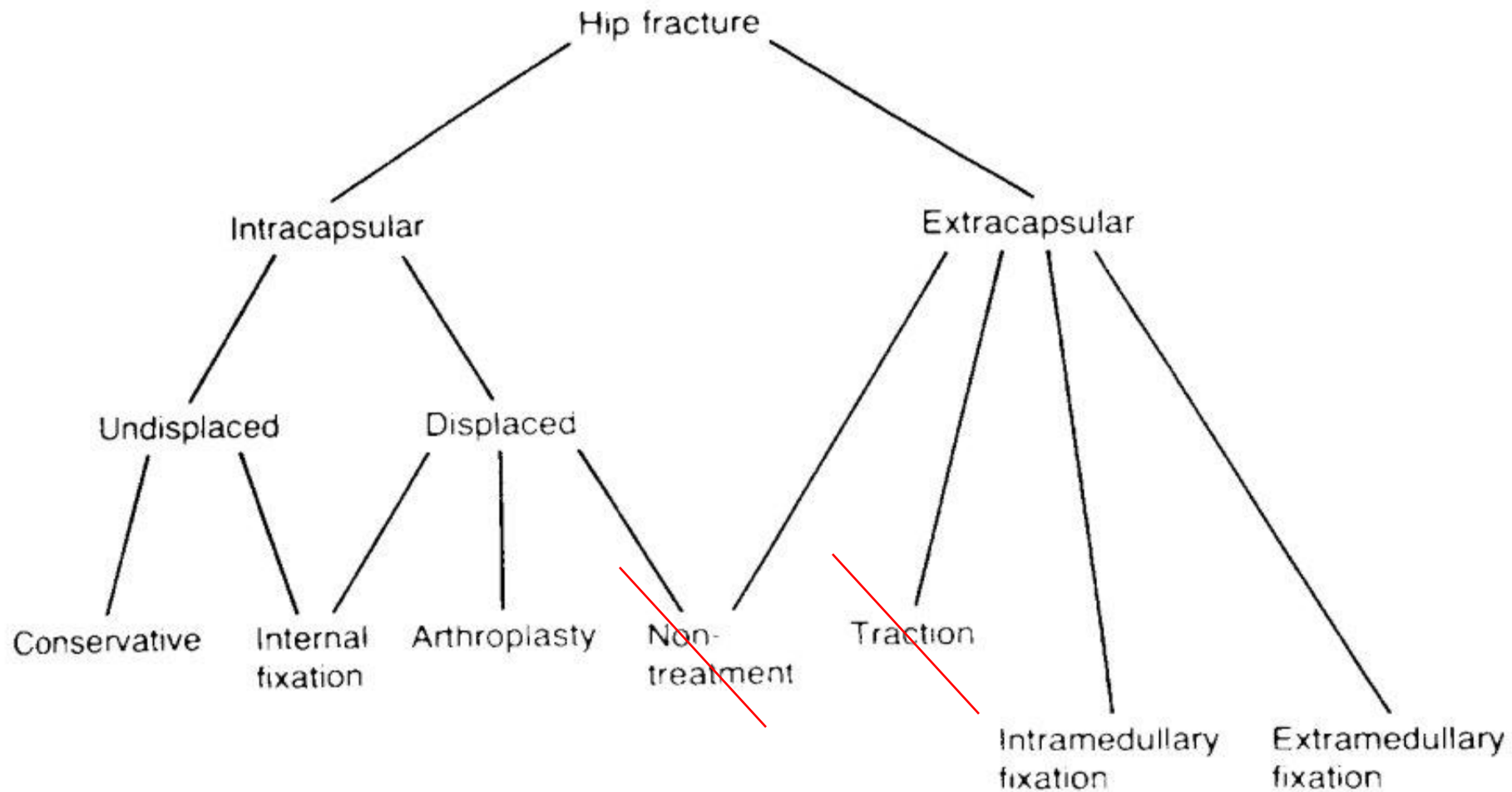


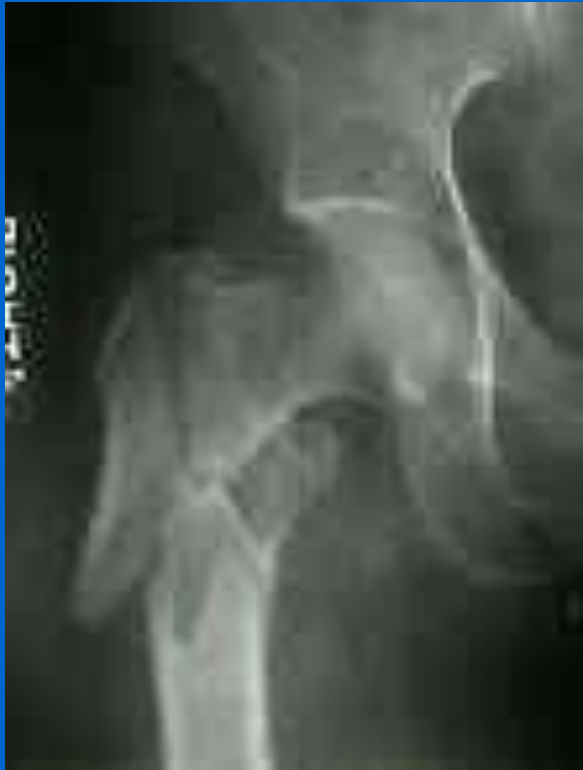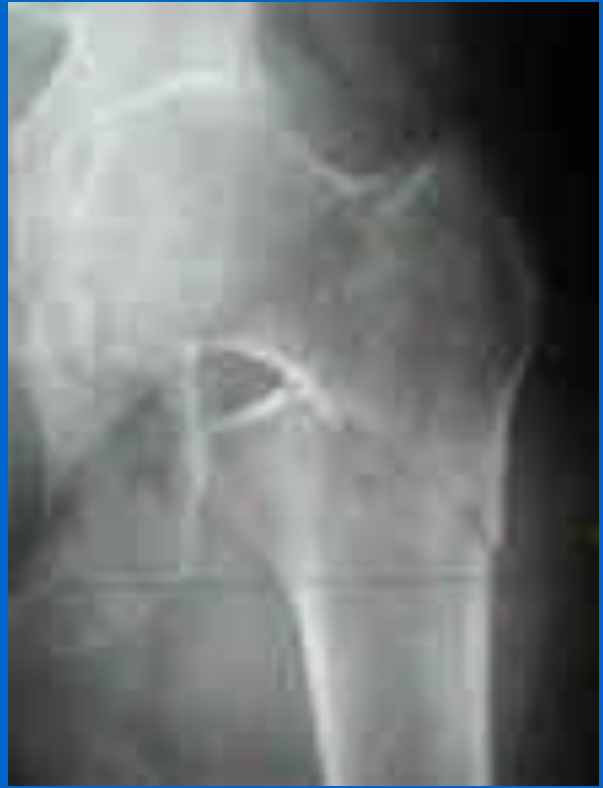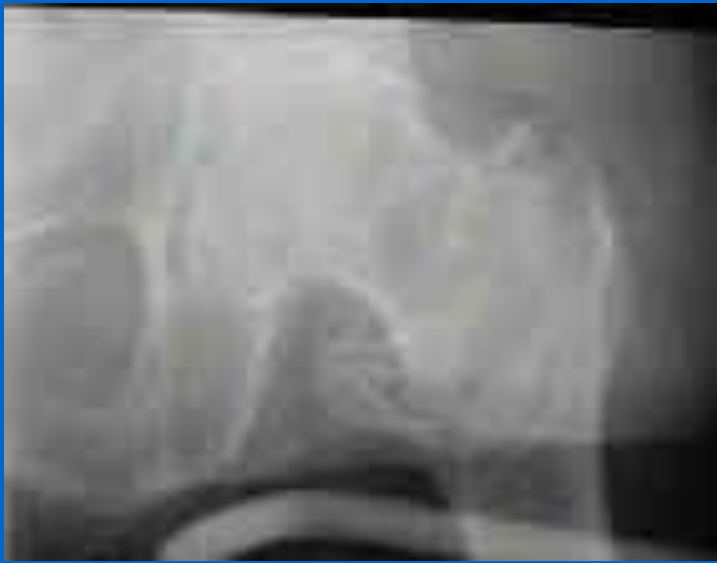- Humeral capitellar angle
- Normally 80 – 85
- Deviation > 5 of other side shouldn't be accepted
- Increase in angle will occur with residual varus & int. rotation deformities

Proximal Femoral Fractures

Common Injury in the elderly patient.

Can occur in young patients in violent accidents.





Intertrochanteric

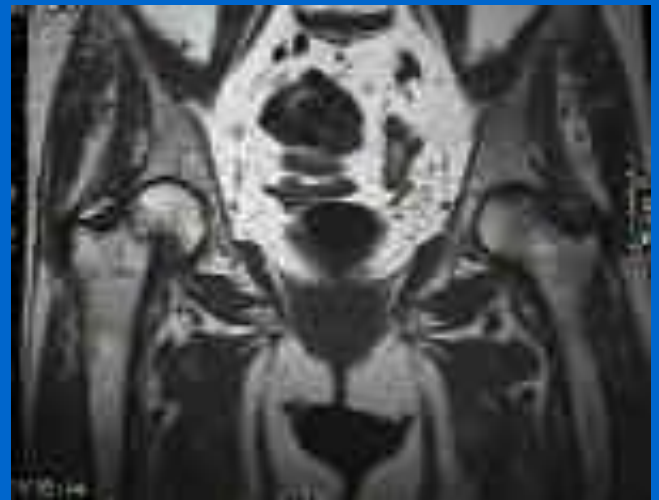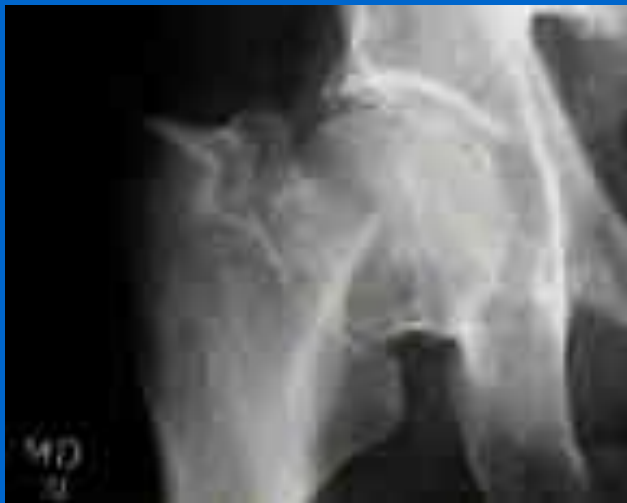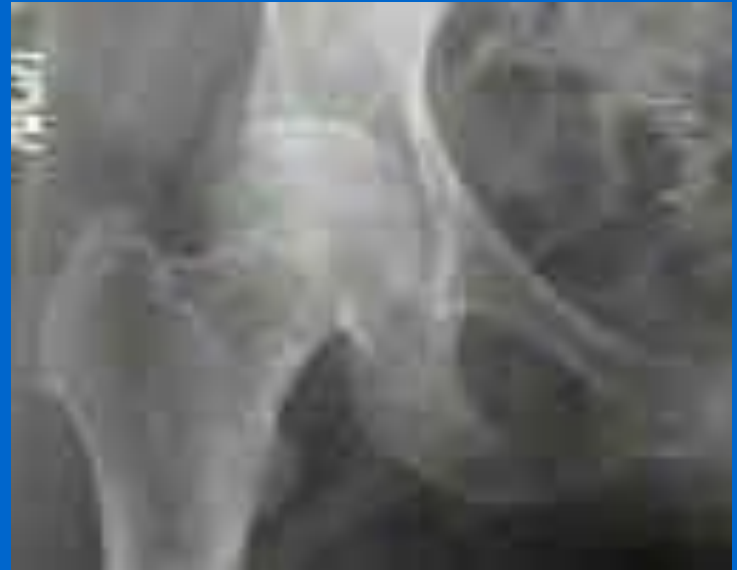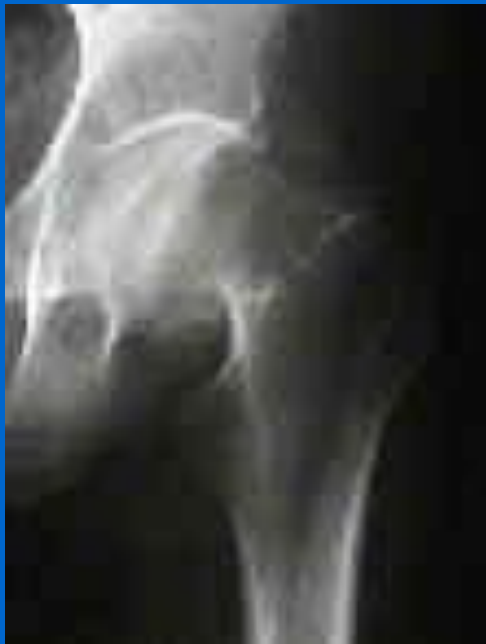Type I: non displaced, stable intertrochanteric s
comminution;

Type II: stable, minimally comminuted, but displaced frx
- 36% of intertroch frx

Type III: has a large posteromedial comminuted area and are
unstable;
- 28% of intertroch frx

Type-IV: consists of an intertrochanteric frx w/ a subtroch
component.
- 15% of intertroch frx;

- **Reversed Obliquity Frx:**

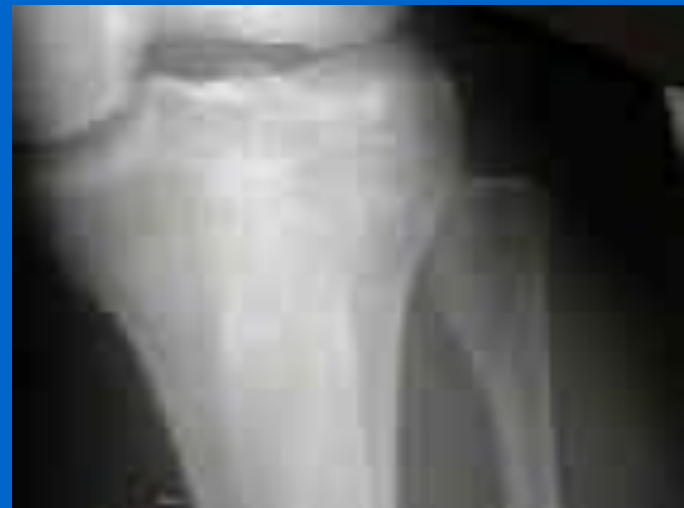
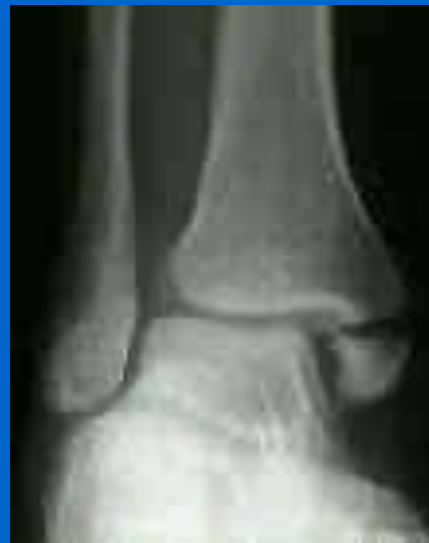
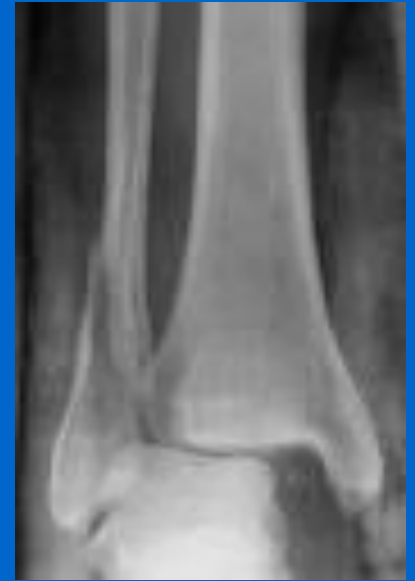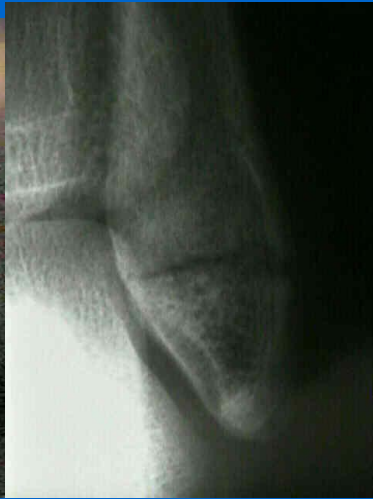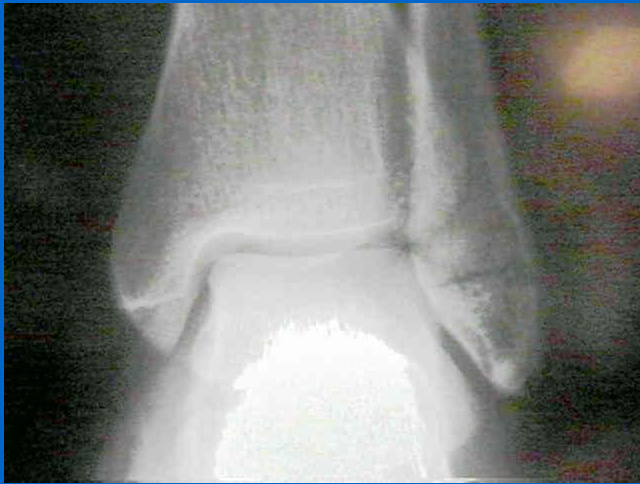Ankle Fractures

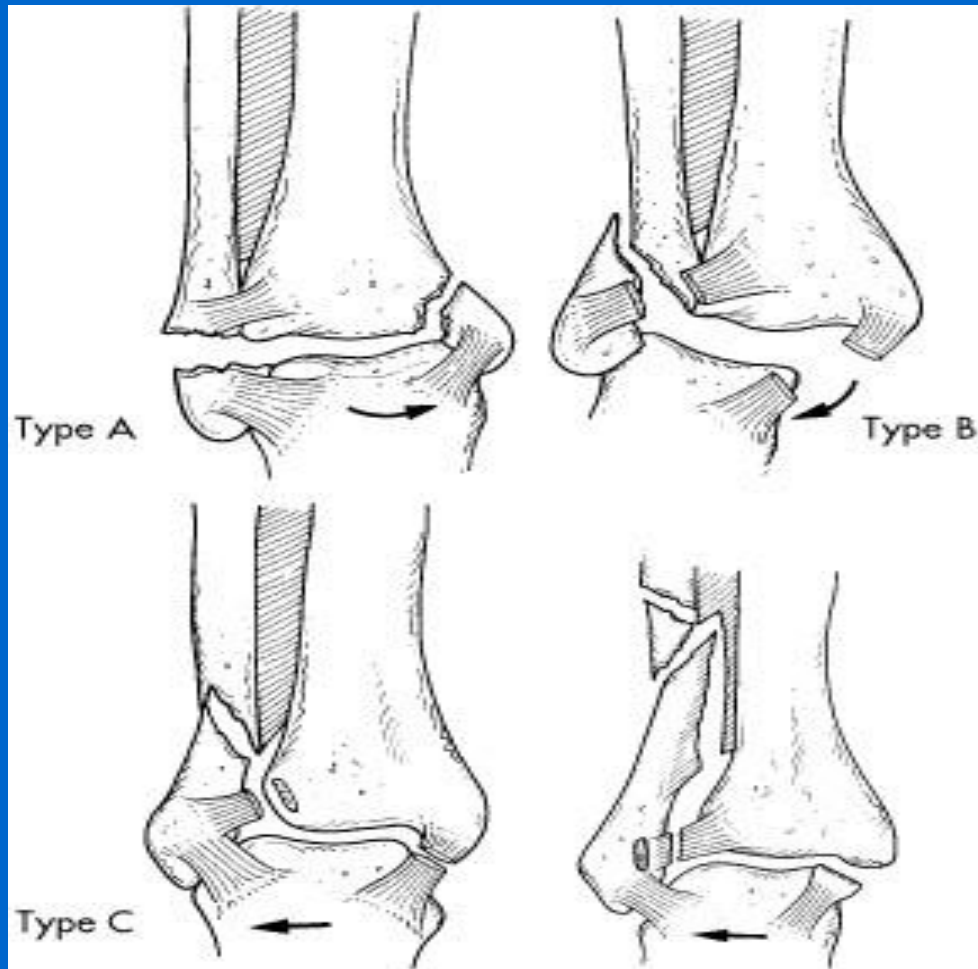
Some History –

Percival Pott

Dupuytren's



Weber Classification



Mosby, Inc. items and derived items
copyright © 2003, Mosby, Inc. All rights reserved.

SUPINATION-ADDUCTION (SA)

1. Transverse avulsion-type fracture of the fibula below the level of the joint or tear of the lateral collateral ligaments
2. Vertical fracture of the medial malleolus

**SUPINATION-EVERSION
(EXTERNAL ROTATION) (SER)**

1. Disruption of the anterior tibiofibular ligament
2. Spiral oblique fracture of the distal fibula
3. Disruption of the posterior tibiofibular ligament or fracture of the posterior malleolus
4. Fracture of the medial malleolus or rupture of the deltoid ligament

PRONATION-ABDUCTION (PA)

1. Transverse fracture of the medial malleolus or rupture of the deltoid ligament
2. Rupture of the syndesmotic ligaments or avulsion fracture of their insertion(s)
3. Short, horizontal, oblique fracture of the fibula above the level of the joint

**PRONATION-EVERSION
(EXTERNAL ROTATION) (PER)**

1. Transverse fracture of the medial malleolus or disruption of the deltoid ligament
2. Disruption of the anterior tibiofibular ligament
3. Short oblique fracture of the fibula above the level of the joint
4. Rupture of posterior tibiofibular ligament or avulsion fracture of the posterolateral tibia

PRONATION-DORSIFLEXION (PD)

1. Fracture of the medial malleolus
2. Fracture of the anterior margin of the tibia
3. Supramalleolar fracture of the fibula
4. Transverse fracture of the posterior tibial surface

From Geissler WB, Tsao AK, Hughes JL: Fractures and injuries of the ankle. In Rockwood CA Jr, Green DP, Bucholz RW, Heckman JD, eds: *Rockwood and Green's fractures in adults*, ed 4, Philadelphia, 1996, Lippincott-Raven.

*Classification groups with injury stages.